

Optimization of the technique for removal of benign tumors and wound suturing in a general surgical hospital

A.G. Izmaylov¹, S.V. Dobrokvashin¹, S.G. Izmaylov²,
A.E. Leontev², E.E. Lukoyanychev², A.A. Bodrov²,
K.V. Kapustin³, A.Yu. Vorontsov³, D.E. Volkov¹

¹Kazan State Medical University, Kazan, Russia;

²City clinical hospital №7 of the Leninskiy region of Nizhny Novgorod n.a. E.L. Berezov, Nizhny Novgorod, Russia;

³Nizhny Novgorod Regional Clinical Oncology Center, Nizhny Novgorod, Russia

Abstract

Aim. To improve the results of surgical treatment in patients with large lipomas by using the device for closing the edges of wounds, allowing local preventive hemostasis in the surgical wound area, to create optimal conditions for atraumatic suturing and thereby reduce the amount of intraoperative bleeding and subsequently reduce the amount of postoperative wound complications.

Methods. The results of treatment of 105 patients with different localization of large lipomas were analyzed. Lipomas ranged from 8.0 to 20 cm in diameter. All patients were divided into 2 groups: the control group consisted of 53 (50.5%) patients for which used the traditional technique of tumor excision with closing surgical wounds, and the study group with 52 (49.5%) patients, for which to reduce tissue damage during tumor removal and the edges of wound suturing, one of the device variants developed by us was used, approximation-distraction device. Fisher's exact test was used for the comparison of the outcomes rate, a p-value <0.05 was considered statistically significant.

Results. Surgical wound complications occurred in 7 (6.7%) of 105 patients. In the study group, surgical wound complications occurred in 1.9% (1 observation), in the control group 11.3% (6 observations). Surgical wound complications were severity grade I and grade IIIa. Complications of the first grade did not require a debridement and will regress on its own; in grade IIIa complications, an opening, excision and drainage surgical wounds were performed without general anesthesia.

Conclusion. Moderate local selective near-tumor tissue compression that occurs when the device branches come closer to each other accelerates spontaneous thrombus formation in damaged small vessels. This creates favorable conditions for the surgeon to work in a “dry” wound.

Keywords: wound complications, hardware, local hemostasis, device for closing the edges of wounds.

For citation: Izmaylov A.G., Dobrokvashin S.V., Izmaylov S.G. et al. Optimization of the technique for removal of benign tumors and wound suturing in a general surgical hospital. *Kazan Medical Journal*. 2020; 101 (4): 579–585. DOI: 10.17816/KMJ2020-579.

Various surgical interventions exist for tumors of the tissue covering them, especially the cranial vault. These tumors are often accompanied by severe bleeding. Significant blood loss is caused not only by the branched vascular network but also by the tumor's anatomical structural peculiarities. Intraoperative blood loss during excision of neoplasms can reach 1000–1200 ml [1–5].

There are various methods, tools, and techniques for performing hemostasis during surgi-

cal interventions for soft tissue neoplasms. These help prevent intraoperative and postoperative bleeding [1–3, 6–8]. Known methods and devices provide hemostasis, but due to the uncontrollability of the tissue compression process (the impossibility of controlled compression), as well as their “blind” suturing, there is a risk of injury to blood vessels and nerve bundles [7–9]. In addition, all the above techniques have significant disadvantages, including increased surgery time (up to 2.5 h), and pos-

sible tissue necrosis in the case of using hemostatic sutures [4], the unreliability of hemostasis, and the complexity of some methods.

The traditional technique of suturing wounds is based on the manual approximation of their edges using various sutures, which are tightened one by one until the tissues are fully adapted. However, in several cases, the use of this method is technically challenging and extremely complicated. For example, when suturing wounds under local anesthesia, or in cases of defects with pronounced tissue rigidity, their reduced extensibility to loads and the asymmetrical position of the opposite edges tend to be fraught with complications [4, 7–10].

Most often, tissue suturing necessitates repeated punctures of tissues to capture a large amount of tissue. This leads to additional trauma (punctures, hematomas, others) and eliminating the blood circulation in significant tissue masses. Moreover, complete closure of the wound edges is not achieved, and “dead spaces” are inevitably formed [11].

Based on the above, it can be assumed that the technical support of wound suturing is currently imperfect and requires the development of less traumatic, accelerated methods that use simple but effective surgical devices. Further improvements in the suturing technique, the creation, and implementation into clinical practice of new types of early adaptations of instrumentation remain indispensable for surgery progress.

We have proposed and manufactured devices that allow for paratumor-like local hemostasis, optimal tissue stretching. Improved stages of wound suturing to increase the efficiency of provisional mechanical hemostasis during the surgical removal of skin tumors and subcutaneous adipose tissue due to uniform hemostatic compression of the tissue surrounding the tumor [12–18].

The first experience using the device we developed for the removal of large lipomas showed its positive technical characteristics during surgical interventions [19]. Later, we conducted a detailed analysis and study of the developed apparatus, which not only modernizes the technique of suturing a postoperative wound and thereby reduces local complications but also has a significant effect on the quality of intraoperative hemostasis. In addition, the article provides an overview of the development and improvement of the surgical technique used to remove tumors in various locations. It analyzes postoperative complications according to the Clavien-Dindo classification and the intraoperative bleeding severity scale, enabling the nature of the bleeding to be standardized, and the study results to be compared.

This article describes one of the options proposed by us together with G.A. Izmailov. It is




Fig. 1. General view of one of the variants of the device for the approximation of the surgical wound edges: 1 — jaws; 2 — screw mechanism; 3 — guide wires. An explanation is provided in the text.

a unique adaptive tool with hardware correction of the wound during its suturing. One of the designed variants of the apparatus (Fig. 1) consists of a toothed rack, a movable jaw and a stationary solid jaw (1), and a screw mechanism (2). The ends of both jaws comprise lateral protrusions that facilitate reliable fixation of the device on the wound, preventing its displacement along the wound surface. The device is made based on a wound retractor and can be manufactured in any workshop. A set of guide wires (3) is supplied with the device. Experimental and clinical studies of prototypes enabled a comparative assessment of the results of surgeries to be conducted. These studies implemented preventive hemostasis and approximated wound edges by manual and mechanical methods.

The technique of preventive, local, selective, hemostasis, and mechanical approximation of the wound edges after tumor removal is as follows. Stepping back by 2–2.5 cm from the tumor’s outer margin, the guide wires are alternately inserted into the skin obliquely outward, followed by eversion of the deeper layers (subcutaneous adipose tissue with fascia capture). They are passed obliquely inward toward the base of the tumor. The end of the wire is withdrawn at the deepest point of the neoplasm plane, after which, with increasing eversion of the tissues. They are punctured under the base of the tumor. The end of the needle is withdrawn from the opposite side of the tumor symmetrically to the puncture site.

The distance of the points of puncture and removal of the wire from the tumor margin should be the same on both sides, without affecting its tissue. The ends of the wire should protrude above the skin from opposite sides of the tumor, stringing its underlying intact tissue layers. The number of wires is determined by the length of the wound. Using the

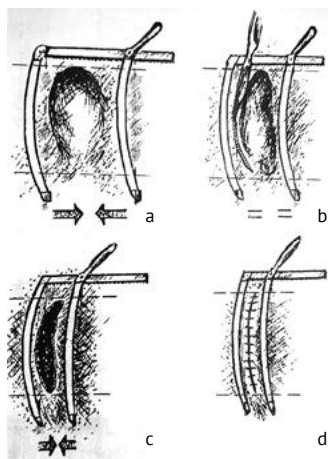


Fig. 2. Schematic representation of the sequence of stages of superficial tissue tumor removal: a — dosed compression; b — radical excision; c — an approximation of the wound edges; d — suturing. Explanations are given in the text.

handle of the rack-and-pinion screw drive mechanism, the jaws are moved apart as much as possible and brought under the ends of all wires that are protruding above the skin. The jaws are then smoothly approximated using the rack-and-pinion screw drive mechanism, causing the tissues to be squeezed along the tumor contour. After removal of the tumor (Figs. 2–4), the jaws are additionally approximated to contact the deepest layers of the wound edges, which are sutured. After that, the overlying layers are aligned with their subsequent suturing. At the end of the surgery, sutures are applied to the skin, and the wires and the device are removed.

The results of treating 105 patients with large soft tissue lipomas at different locations were analyzed. The sizes of lipomas ranged from 8.0 to 20 cm in diameter. There were 38 men (36.2%) and 67 women (63.8%). Most often, lipomas were located on the back (56 cases (53.3%)), on shoulder joints (10 cases (9.5%)), on the upper limbs (39 cases (37.1%)). The average age of the patients was 49 ± 8.1 years. The age ratio was 48 ± 6.2 years in the comparison group and 47.5 ± 5.75 years in the main group ($p = 0.98$) when comparing the groups by gender, $p = 0.98$. The patients were representative by gender, age, and comorbidities.

The patients were distributed into two groups, namely the clinical comparison group included 53 (50.5%) patients, which used the traditional method of the lesion excision with suturing of the postoperative wound; and the study group consisting of 52 (49.5%) patients, which used one of the variants of the apparatus developed, namely an approximation-distraction device to approximate the edges of wounds to reduce tissue trauma during removal of the lesion and match the edges of the wound during tissue suturing.

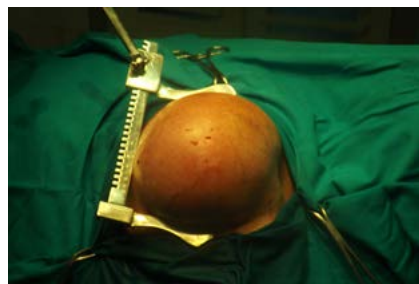


Fig. 3. General view of the device for the approximation of the wound edges when removing the lipoma of the soft tissues of the back.

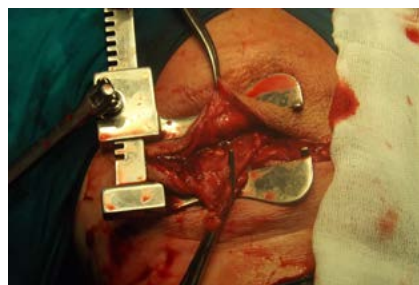


Fig. 4. View of the operating wound without signs of external hemorrhage. Stage of the operating wound suturing.

According to Redon, the wound cavity was drained in all patients according to indications with the establishment of a rubber tube drainage or active drainage. The indications included pronounced subcutaneous fatty tissue, pockets formed during lipoma excision, and instability of hemostasis.

The postoperative local complications in the groups of patients were analyzed using the Clavien–Dindo classification [20]. The volume of blood loss during the surgery was assessed according to the scale of the severity of intraoperative bleeding [21]. An ultrasound examination of the sutured wound area was used to control the course of the wound process. This enabled the nature of the tissue echogenicity of this zone in time, the location of the pathological foci to be determined, and their size and configuration to be assessed [22].

Data analysis was performed in the environment for statistical calculations R 3.4.4. To analyze the differences in the frequency of the outcomes studied in the groups of patients, Fisher's exact test was used, and the differences were considered statistically significant at $p < 0.05$.

The clinical application of the approximation-distraction apparatus for the removal of lipomas of various sizes has demonstrated its advantage over traditional methods. Optimal conditions are created for radical tumor removal with a minimum amount of blood loss (Table 1). The tumor was compressed gradually without significant effort, which was determined by the degree

Clinical experiences

Table 1. The severity of intraoperative hemorrhage when using hardware and traditional excision methods of soft tissue lipomas (classification of hemorrhage, adopted by the U.S. FDA) [21]

Group of patients	Degree I, more than 1–5 ml/min (leakage)	Degree II, more than 5–10 ml/min (onflow)	Degree III, more than 10–50 ml/min (strong)	Degree IV, more than 50 ml/min (flow)
Study (52 patients)	45 (86.5%)	7 (13.4%)	—	—
Clinical comparison (53 patients)	24 (45.3%)	28 (52.8%)	1 (1.9%)	—
Total	69 (65.7%)	35 (33.3%)	1 (0.9%)	—

Note: FDA (Food and Drug Administration) — the U.S. Federal Service for control over production, storage, and sale of food products, medicines, and cosmetics; the significance of differences in severity for different treatments $p < 0.0001$.

Table 2. The structure of postoperative wound complications in the study group of patients and the clinical comparison group, by severity according to the Clavien-Dindo classification [19, 20]

Wound complications	Study group (n = 52)		Clinical comparison group (n = 53)		Total
	I	IIIa	I	IIIa	
Seroma	—	—	1	—	1
Hematoma	—	1	—	3	4
Marginal wound necrosis	—	—	—	2	2
Total, $n_1 = 1$, $n_2 = 6$	—	1	1	5	7 (100%)

Note: I, IIIa — the severity of complications; n_1 and n_2 — the total number of complications in the main group of patients and the comparison group, respectively. The explanation is given in the text.

of resistance on the handle of the approaching mechanism and the skin's appearance.

Clinical experience has shown that a tissue suture created using hardware compression and rapid isolation of the postoperative wound from the external environment has good physical and biological adaptation. Due to this, favorable conditions are created for wound healing by primary intention with a minimal inflammatory reaction and an extremely low development of scar tissue. This significantly reduces the risk of suture failure. The results obtained in the clinical application of the proposed device for mechanical provisional arresting of hemorrhage and the approximation of the wound edges enable it to be recommended for broader use in surgical practice for the removal of benign soft tissue tumors.

In the process of working with the device, the following positive design aspects were established:

- the presence of bends in the jaws of the modified device prevents the emergence of areas of excessive pressure of the jaws on the adjacent tissues and ensures uniform traction of tissues;
- the absence of tension of the tissues in the area of suture imposition prevents thread eruption and suture failure;
- the passage of the Kirshner wires over the device's jaws ensures their mobility and enables accurate manual matching of the tissue's edges.

The postoperative wound complications in patients in the clinical comparison group included hematomas in 3 (5.7%) cases and seroma in 1 (1.9%) case. In the study group, 1 (1.9%) patient had a hematoma. Marginal wound necrosis in the clinical comparison group was registered in 2 (3.8%) patients; this complication was not noted in the study group.

Early postoperative complications in wounds occurred in 7 (6.7%) of 105 patients (Table 2). In the study group, wound postoperative complications amounted to 1.9% (1 case), while in the clinical comparison group, they were noted in 11.3% (6 cases; $p = 0.1125$). Postoperative wound complications were of severity grades I and IIIa. Complication degree I was represented by seroma less than 25 mm, which did not require revision of the wound and regressed independently during the basic drug therapy. In case of complications of the grade of severity IIIa, the hematomas were incised and drained, and the altered tissues were excised without general anesthesia.

Occasionally, the slight bleeding noted from the puncture sites with the wires after removal of the apparatus was short term and usually stopped spontaneously or with slight short term pressure with a gauze ball. If necessary, we used electrocoagulation to stop bleeding from small vessels during the surgery. Due to the probability of bleeding in the

immediate postoperative period, ligation of large vessels was performed using an absorbable monofilament suture.

CONCLUSIONS

1. Dosed and controlled hardware compression of tissues leads only to local preventive hemostasis only in the surgical wound area without stopping the blood flow in the surrounding tissues, thereby creating favorable working conditions for the surgeon in a “dry” wound.

2. The proposed device for hardware wound correction greatly facilitates the main stages of suturing, namely tissue piercing, passing, pulling up, and tangling of the thread, and knotting.

3. The encouraging results of the clinical application of the proposed device for mechanical provisional hemostasis and approximation of the wound edges enable it to be recommended for use in surgical practice.

4. Improvement of the surgical and instrumental technology for the removal of large soft tissue lipomas, including the development of adaptive instruments for controlled intraoperative mechanical hemostasis and approximation of the wound defect edges, enabled postoperative complications in wounds to be reduced and the volume of blood loss to be compared with the traditional surgical technique.

Authors' contributions. S.V.D. was the head of work, A.G.I., S.G.I., A.E.L., and E.E.L. conducted the research, A.A.B., K.V.K., A.Yu.V., and D.E.V. were responsible for collecting and analysis of the results.

Funding. The study had no external funding.

Conflict of interest. The authors declare no conflict of interest related to the article presented.

REFERENCES

- Aslanov E.G. Skin plastic in oncology. *Voprosy onkologii*. 1959; (5): 34–36. (In Russ.)
- Mindlin G.Y. Hemostatic clamp, in *Respublikanskiy sbornik izobreteniy i rats. predlozheniy meditsinskikh vuzov i NII MZ RSFSR*. (Republican collection of inventions and rational proposals of medical universities and research institutes of the Ministry of Health of the RSFSR.) Moscow. 1979; 43–44. (In Russ.)
- Feins N.R., Rubin R., Borger J.A. Abulatory serial excision of giant nevi. *J. Pediatr. Surg.* 1982; 17 (6): 851–854. DOI: 10.1016/S0022-3468(82)80456-9.
- Izmailov G.A., Orenburov P.Y., Dyatlov E.E. et al. Device for temporarily stopping bleeding during surgical removal of a tumor of the skin and subcutaneous tissue. *Voprosy onkologii*. 1991; 37 (6): 749–750. (In Russ.)
- Izmailov A.G., Dobrokvashin S.V., Volkov D.E. et al. Concept of prevention and treatment of postoperative wound complications in surgical patients. *Prakticheskaya meditsina*. 2017; (6): 50–54. (In Russ.)
- Kiselev L.V. Method for treating of hemangiomas. USSR Inventor's Certificate SU1076100A. Bulletin №8, issued at 22.03.1982. (In Russ.)
- Izmailov S.G., Izmailov G.A. *Novye tekhnologii v khirurgii ran*. (New technologies in wound surgery.) N. Novgorod: Izd-vo NGMA. 2004; 340 p. (In Russ.)
- Izmailov S.G., Izmailov G.A., Podushkina I.V. et al. *Lechenie ran*. (Treatment of wounds.) Kazan: Izd-vo KGTU. 2003; 290 p. (In Russ.)
- Izmailov S.G., Izmailov G.A. *Profilaktika ranevykh oslozhneniy v abdominal'noy khirurgii*. (Prevention of wound complications in abdominal surgery.) Kazan: Izd-vo KGTU. 1996; 192 p. (In Russ.)
- Usoltsev D.M., Davidyan A.A., Babich R.A. The experience of removal of giant lipomas in an ambulatory surgery centre. *Statsionarozameshchayushchiye tekhnologii: Ambulatornaya khirurgiya*. 2016; (1–2): 94–96. (In Russ.)
- Mikhailichenko V.Yu. Tatarchuk P.A., Shestopalov D.V. et al. Application of devices for the closing of wounds in surgery. *Vestnik neotlozhnoy i vosstanovitel'noy khirurgii*. 2019; 4 (1): 92–103. (In Russ.)
- Izmailov G.A., Zelenov E.S. A Device for Closing the Edges of Wounds. USSR Inventor's Certificate №1106489, issued at 12.06.1983. *Inventions*. 1984; 29: 10. (In Russ.)
- Izmailov G.A., Zelenov E.S. A device for closing the edges of wounds. USSR Inventor's Certificate №1217370, issued at 01.09.1984. *Otkrytiya*. 1985; 10: 22. (In Russ.)
- Izmailov G.A., Zelenov E.S. A device for closing the edges of wounds. USSR Inventor's Certificate №1243708, issued at 04.02.1985. *Otkrytiya*. 1986; 26: 16. (In Russ.)
- Izmailov G.A., Orenburov P.Ya., Dyatlov E.E. et al. A device for closing the edges of wounds. USSR Inventor's Certificate №1387999, issued at 05.05.1986. *Otkrytiya*. 1988; 14: 27. (In Russ.)
- Izmailov G.A., Orenburov P.Ya., Dyatlov E.E. et al. A device for closing the edges of the wound used in surgery of tumors. USSR Inventor's Certificate №1404064, issued at 28.01.1987. *Otkrytiya*. 1988; 23: 24. (In Russ.)
- Izmailov G.A., Dyatlov E.E., Orenburov P.Ya. et al. A device for closing the edges of wounds. USSR Inventor's Certificate №1438737, issued at 20.04.1987. *Otkrytiya*. 1988; 43: 22. (In Russ.)
- Izmailov S.G., Izmailov G.A., Reznik V.S. et al. *Approximation-distraction apparatus*. Patent for invention №67428. Bulletin №19, issued at 27.09.2007. (In Russ.)
- Izmaylov A.G., Dobrokvashin S.V., Volkov D.E. et al. Instrumental correction during surgical treatment of patients with large soft tissue lipomas. *Kazan Medical Journal*. 2016; (6): 1003–1006. (In Russ.) DOI: 10.17750/KMJ2016-1003.
- Dindo D., Demartines N., Clavien P.A. Classification of surgical complications: a new proposal with evaluation in a cohort of 6336 patients and results of a survey. *Ann. Surg.* 2004; 240 (2): 205–213. DOI: 10.1097/01.sla.0000133083.54934.ae.
- Lewis K.M., Li Q., Jones D.S. et al. Development and validation of an intraoperative bleeding severity scale for use in clinical studies of hemostatic agents. *Surgery*. 2017; 161 (3): 771–781. DOI: 10.1016/j.surg.2016.09.022.
- Izmailov S.G., Bodrov A.A., Lazarev V.M. et al. A method for predicting purulent-inflammatory complications of postoperative wounds. Patent for invention №2160560. Bulletin No. 35, issued at 20.12.2000. (In Russ.)